



PATIENT

Chips Scheerer

SPECIES

Canine

BREED

Corgi

SEX

MN

AGE

4

WEIGHT

35

INTERPRETED BY

R. McKenzie Daniel,
DVM, DABVP
(Canine and Feline)

IMAGING PERFORMED BY

Jenn

HOSPITAL NAME

Rockaway Animal
Hospital

REFERRING VET

Dr Maniar

INVOICE

23063

DATE

11/25/2025

PRESENTING CLINICAL SIGNS

vomiting profusley

Abnormal PE/Chem/CBC/UA Results: HCT 64.9% Na 166 Chlor 139 ALB 4.2 ALP >10

ULTRASONOGRAPHIC EXAMINATION OF THE ABDOMEN

Urinary System

The urinary bladder, trigone, cystourethral junction, and visible pelvic urethra exhibited normal thickness and tone. Anechoic urine was present in the lumen with no evidence of urine/lumen sediment, mineral, or calculi. The ureteral papillae were normal. The ureters were not visible which is normal. No evidence of inflammatory or neoplastic changes was noted.

Normal size and margination were present in the kidneys. A normal 1:3 cortex / medulla ratio and normal corticomedullary definition were maintained. The echogenicity of the cortex was similar to or slightly less than normal liver parenchyma while the medulla echogenicity was hypoechoic to the cortex with no evidence of pelvic dilation. The left kidney measured 4.8 cm in length. The right kidney measured 5.1 cm in length.

The area of the aortic trifurcation was free of pathology.

The area of the residual prostate appeared normal and free of pathology.

Adrenal Glands

The left adrenal gland was uniform in size and contour with a uniformly hypoechoic parenchyma. The left adrenal gland measured 0.56 cm width at the caudal pole. The right adrenal gland was uniform in size and contour with a uniformly hypoechoic parenchyma. The right adrenal gland measured 0.65 cm width at the caudal pole.

Spleen

The spleen exhibited a finely textured and homogenous parenchyma which was hyperechoic to the liver and renal cortical parenchyma. The capsule was smooth and regular without apparent expansion. The splenic vasculature at the hilus was normal in volume with no evidence of congestion or thrombosis. Acute to chronic inflammatory, neoplastic, or benign parenchyma changes were not noted.

Liver/Gallbladder

The liver was subjectively normal in size, structure, and contour. The liver parenchyma was uniform and hypoechoic to the spleen with a mild coarse echotexture. Normal vascular volume. The hepatic and portal vasculature were normal in appearance without signs of congestion. The gallbladder was non-distended in size with thin walls and primarily anechoic luminal content. The cystic and common bile ducts were normal.

Gastrointestinal

The stomach presented intact wall layering with a normal wall layer ratio. The lumen of the stomach contained mild non-shadowing chyme and lumen gas with no signs of ileus, obstruction or foreign material.



PATIENT

Chips Scheerer

SPECIES

Canine

BREED

Corgi

SEX

MN

AGE

4

WEIGHT

35

INTERPRETED BY

R. McKenzie Daniel,
DVM, DABVP
(Canine and Feline)

IMAGING PERFORMED BY

Jenn

HOSPITAL NAME

Rockaway Animal
Hospital

REFERRING VET

Dr Maniar

INVOICE

23063

DATE

11/25/2025

The small intestine presented intact wall layering with 1:3 muscularis/mucosa ratio. The lumen of the small intestine was empty with no signs of mechanical/metabolic ileus, obstruction or foreign material.

Normal visible colon wall layers were present with apparent formed feces in lumen.

Pancreas

The parenchyma of the left limb, body and right limb of the pancreas presented isoechoic to the adjacent omental fat. A normal curvilinear capsule contour of the pancreas was present. The visible pancreatic duct was normal. No signs of active inflammation or neoplastic disease was evident.

Free Abdomen

No omental masses, overt lymphadenopathy or peritoneal effusion was present.

ULTRASONOGRAPHIC FINDINGS

Primary

- Normal gastrointestinal tract with mild retained non-shadowing gastric chyme
- Normal area of pancreas.

INTERPRETATION OF THE FINDINGS & FURTHER RECOMMENDATIONS

No evidence of gastrointestinal obstructive pattern, foreign material or sonographically active pancreatitis.

Gastrointestinal support should prove beneficial. Recheck sonogram if non-responsive or progressive gastrointestinal signs is recommended.



PATIENT

Chips Scheerer

SPECIES

Canine

BREED

Corgi

SEX

MN

AGE

4

WEIGHT

35

INTERPRETED BY

R. McKenzie Daniel,
DVM, DABVP
(Canine and Feline)

IMAGING PERFORMED BY

Jenn

HOSPITAL NAME

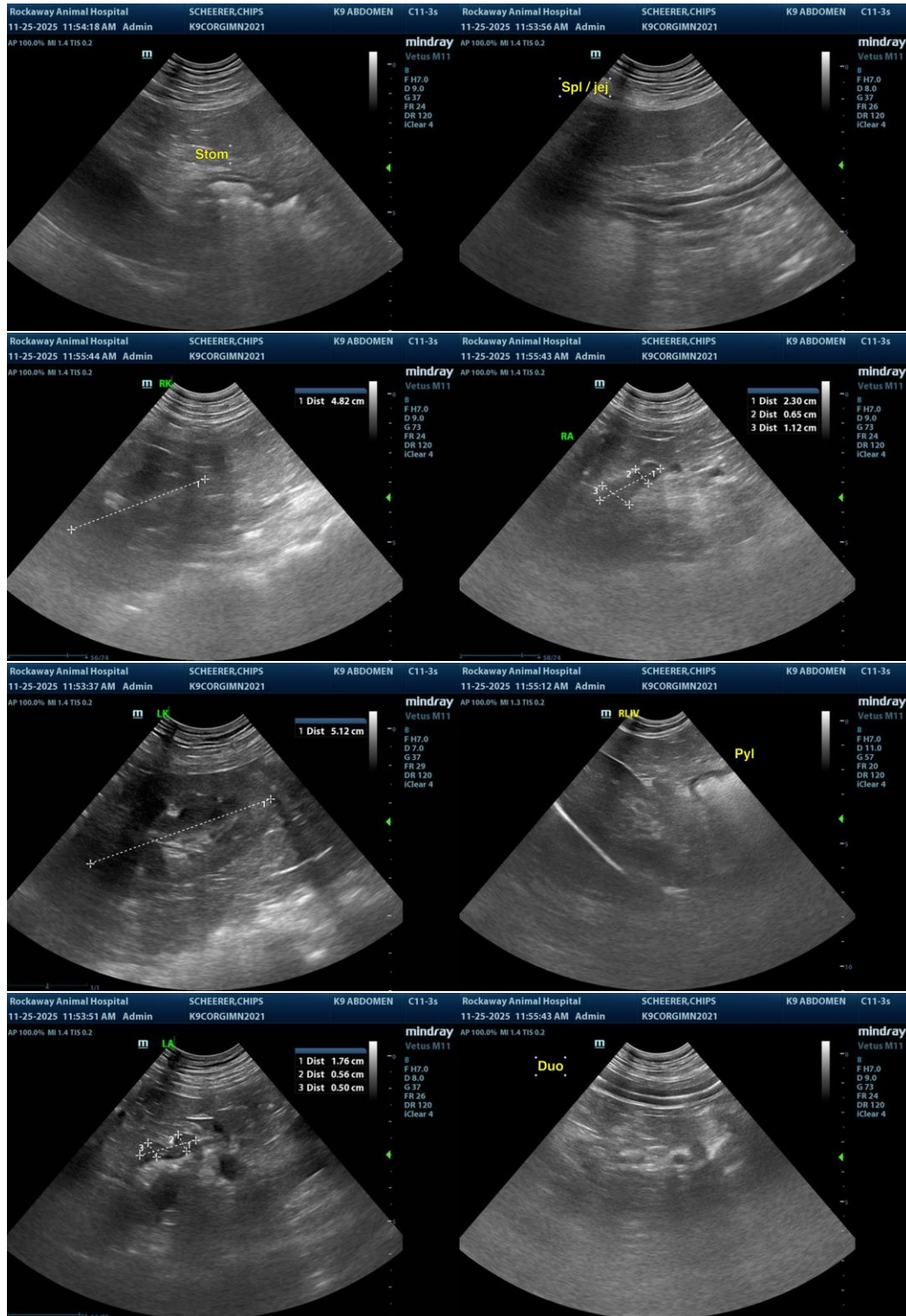
Rockaway Animal
Hospital

REFERRING VET

Dr Maniar

INVOICE
23063

DATE
11/25/2025



The information and recommendations provided are based on the images presented by the referring veterinarian/sonographer. No evaluation can be communicated regarding pathology that was not



PATIENT

Chips Scheerer

visible in the image/video clips provided.

Thank you for this referral. If the clinical or image interpretation does not parallel your findings or if I can be of any further assistance, please contact me.

SPECIES

Canine

R. McKenzie Daniel, DVM, DABVP (Canine/Feline Practice)
info@sonopath.com

BREED

Corgi

SEX

MN

AGE

4

WEIGHT

35

INTERPRETED BY

R. McKenzie Daniel,
DVM, DABVP
(Canine and Feline)

IMAGING PERFORMED BY

Jenn

HOSPITAL NAME

Rockaway Animal
Hospital

REFERRING VET

Dr Maniar

INVOICE 23063

DATE
11/25/2025